

**GOLD COAST UNIVERSITY HOSPITAL
EMERGENCY DEPARTMENT
1 HOSPITAL BOULEVARD**

DISCHARGE LETTER
CONFIDENTIAL



Emergency Department
Gold Coast University Hospital
1 Hospital Boulevard
Southport QLD 4215

March 8, 2015
806010 RESUS
UNKNOWN
UNKNOWN
Age 114 yrs
UR Num 806010

MR JOHN
DEPP.

669163

Dear NO,

806010 RESUS presented to the Emergency Department at Gold Coast University Hospital on the 8 MAR 2015 at 16:20. The presenting problem was INJURY.

The diagnosis was # OF FINGER.

Thanks for seeing and treating this patient. He sustained an injury to his right middle finger tonight after accidentally cutting it with a kitchen knife. He has an oblique de-tipping injury that commences distal to the DIPJ on the ulnar side and runs obliquely to the midline of the tip of the finger. Xray shows a comminuted # of the tuft and an oblique fracture more proximally suggestive of a crushing mechanism. His doctor did bring in a small fragment of tissue that felt abnormally firm - hard and was felt to be unsuitable for a graft. He had a ring block with ropivacaine and the wound was cleaned by Dr Raja Sawhney (plastic / hand surgeon) after further supplementation of the ring block with additional bupivacaine. His tetanus was updated and he received a single dose of iv ticarcillin-clavulanate 3.1 g.

Unfortunately he will not be able to continue working until the finger is well healed and this will be several weeks. His private doctor has a supply of augmentin and will administer twice daily.

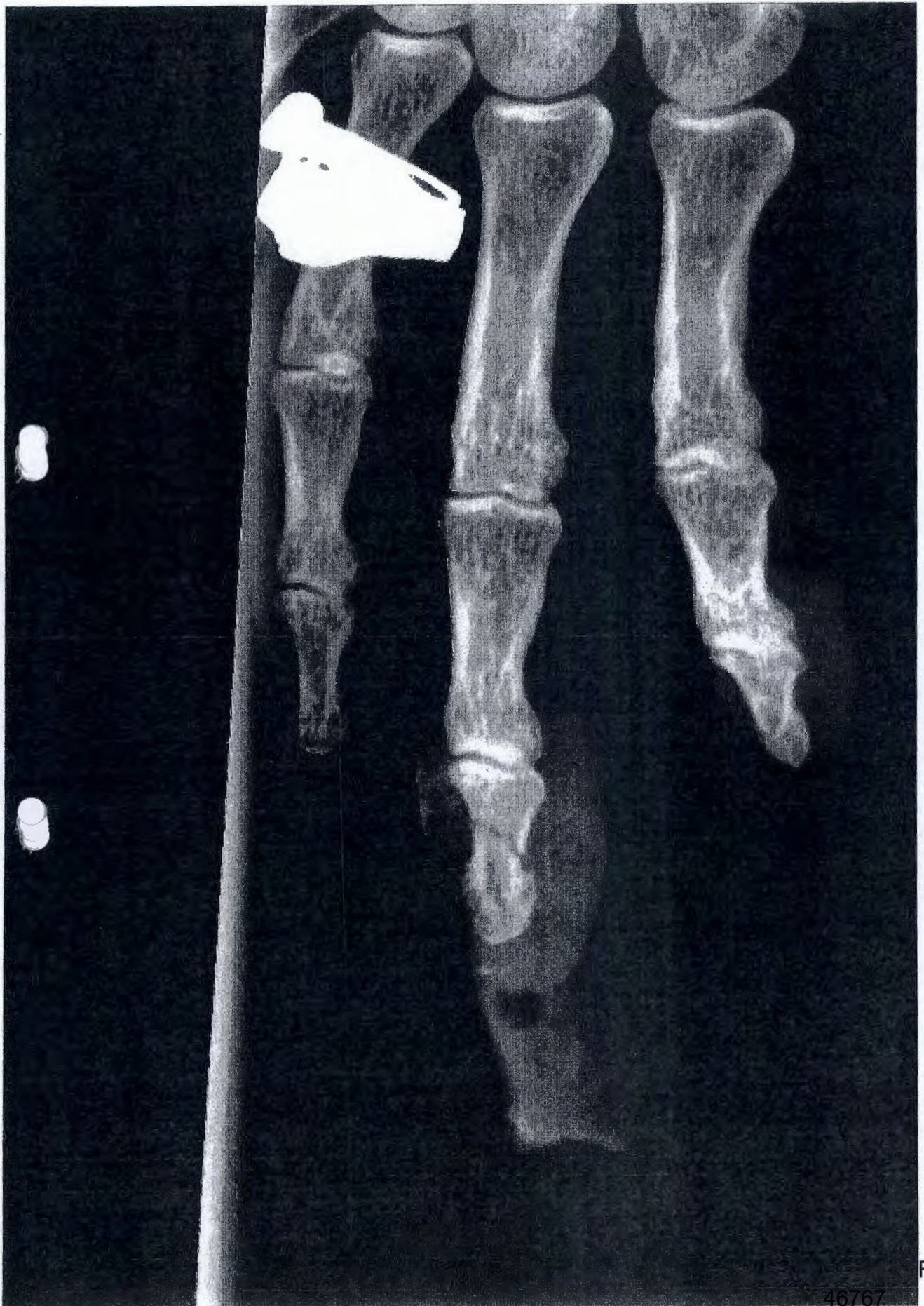He will be followed up tomorrow by Dr Sawhney and surgical options discussed.

Steve Dr Grant

STEVE DR GRANT
CONSULTANT / VMO / SMO

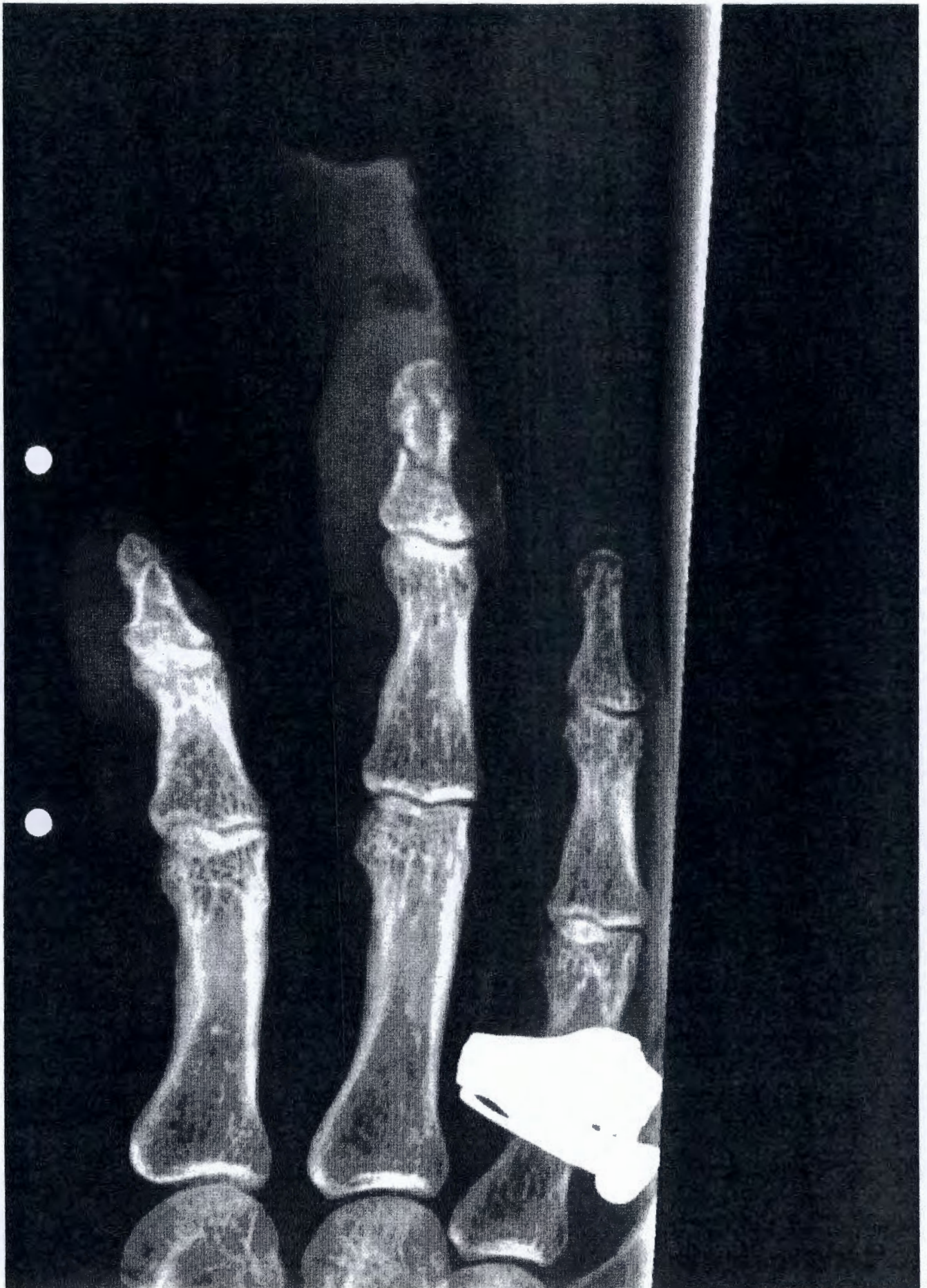
PLT / Def: 300
Date 04/11/2022
Judge ID ONLY
Case # CL-2019-2911

F761
46766
DEPP00011506



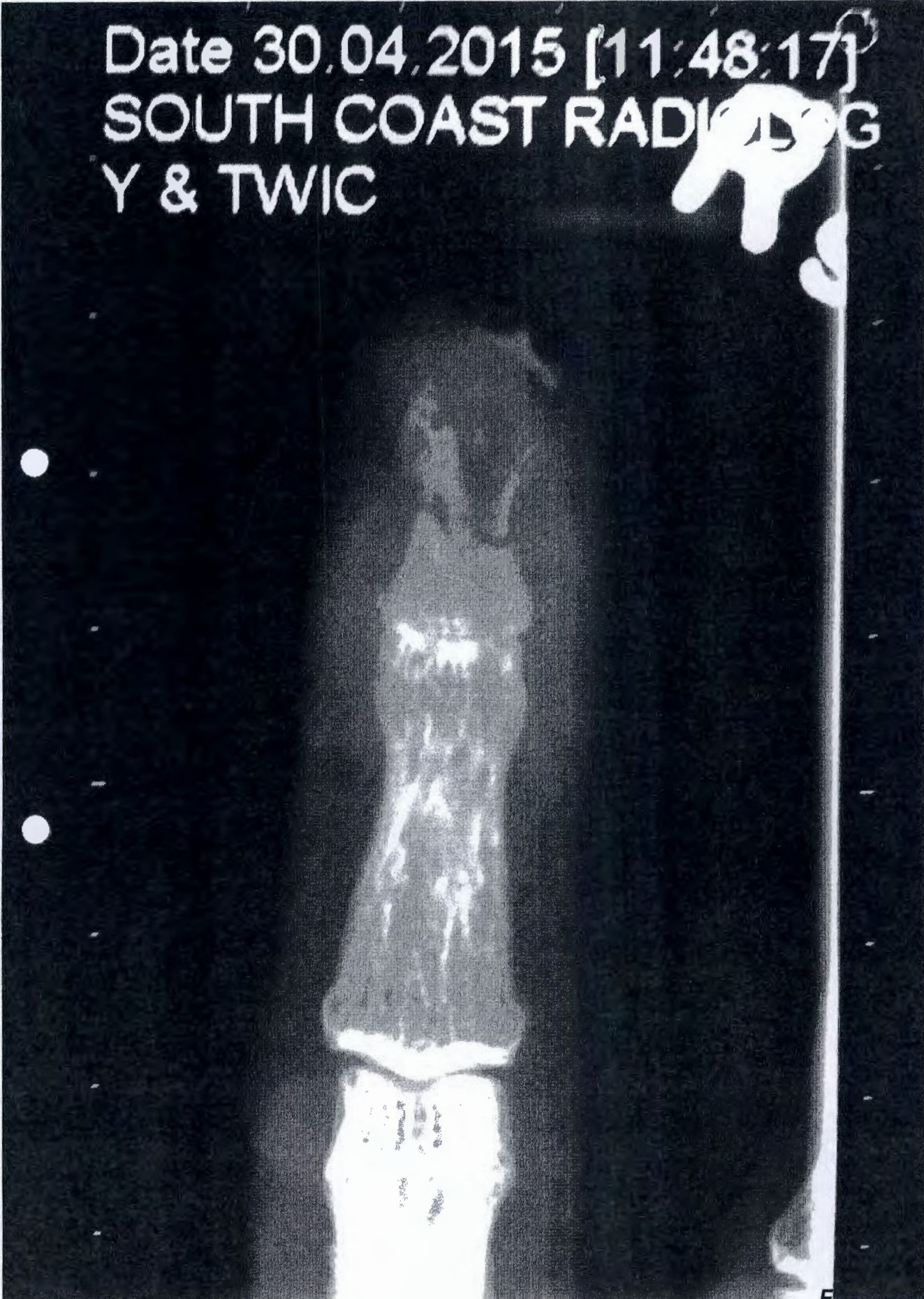
F762

46767

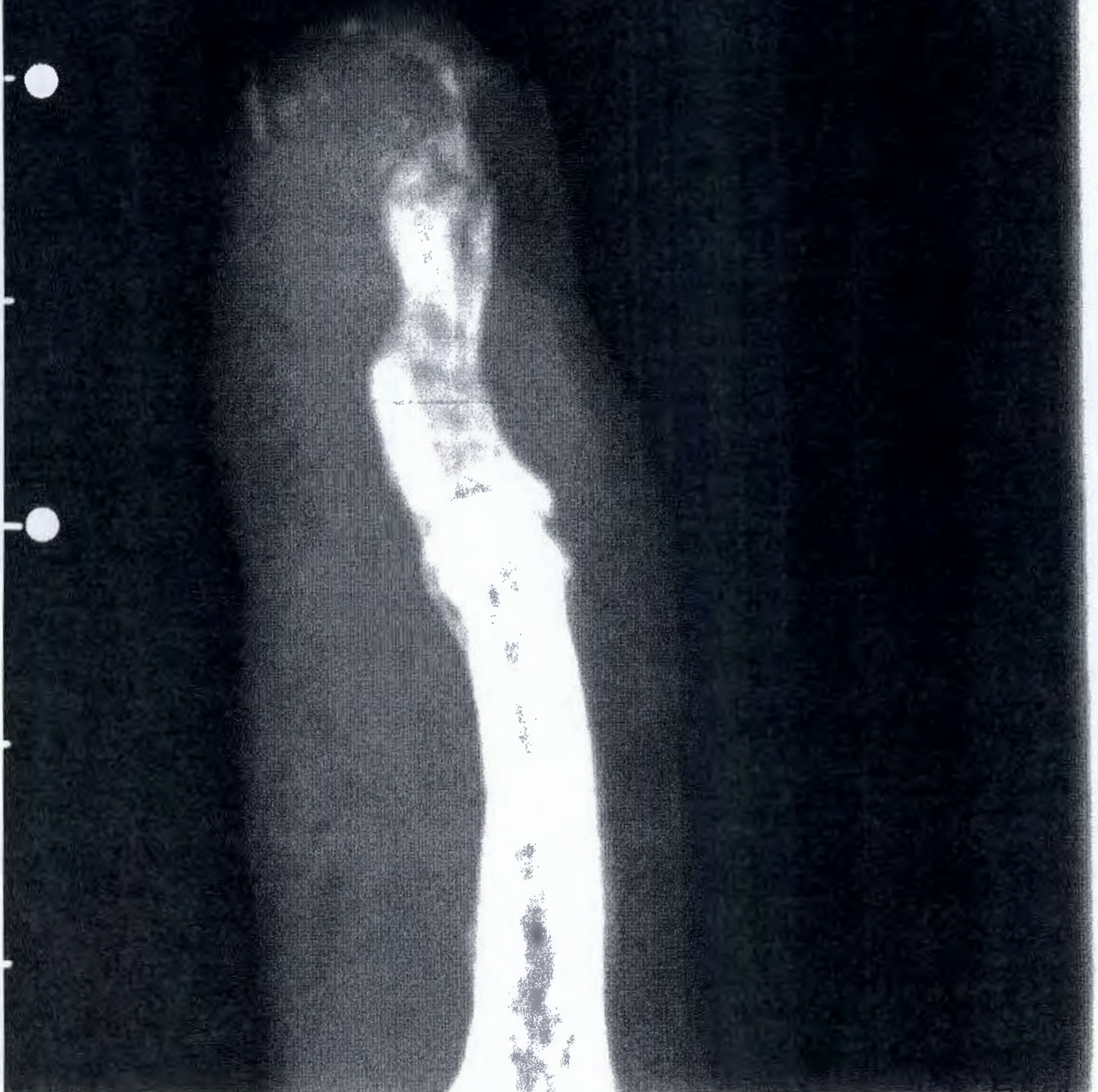

46768'

Date 30.04.2015 [11:48:17]
SOUTH COAST RADIOLOGY
& TWIC



SOUTH COAST RADIOLOGY
& TWIC



46771